



THE INDOONESIAN SOCIETY OF
INTERVENTIONAL CARDIOLOGY
PERKIPERKARDIOLOGI INTERVENSI



Is It Time To Let It Go?

ANTONIA ANNA LUKITO

CARDIOVASCULAR DEPT PELITA HARAPAN UNIVERSITY

SILOAM LIPPO VILLAGE HOSPITAL

INDONESIA

History of Illness

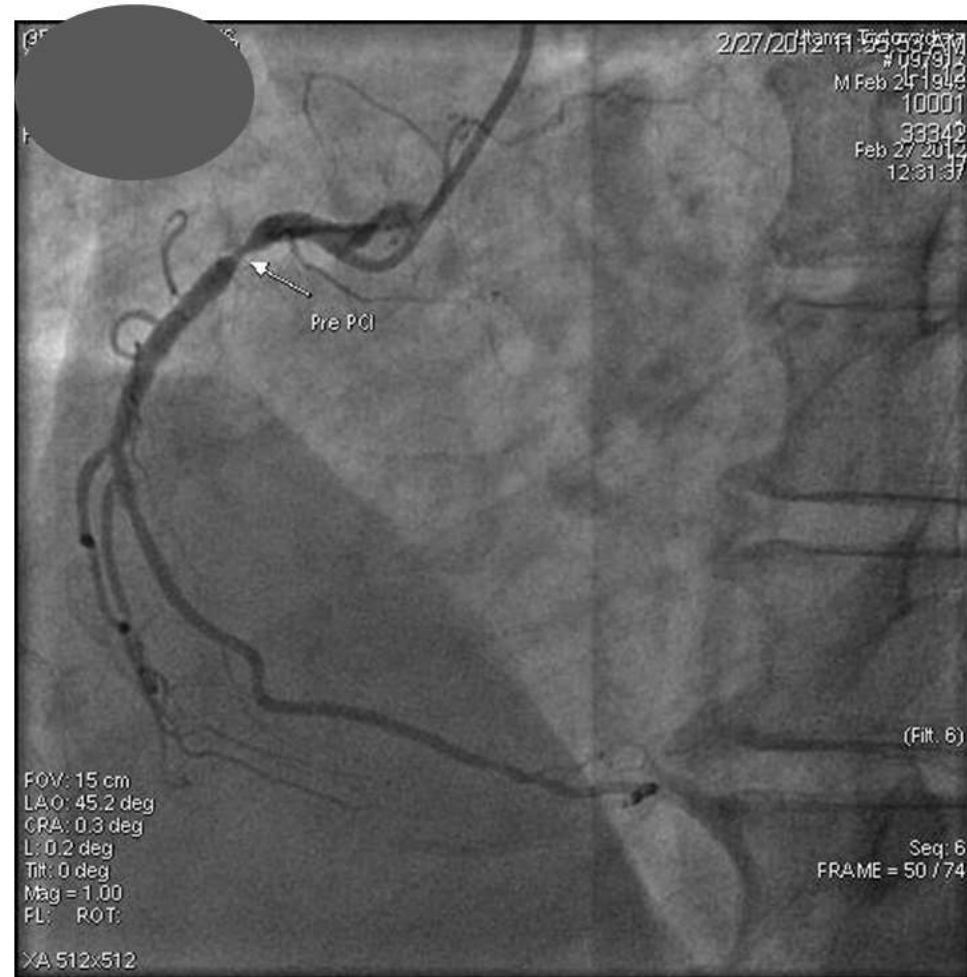
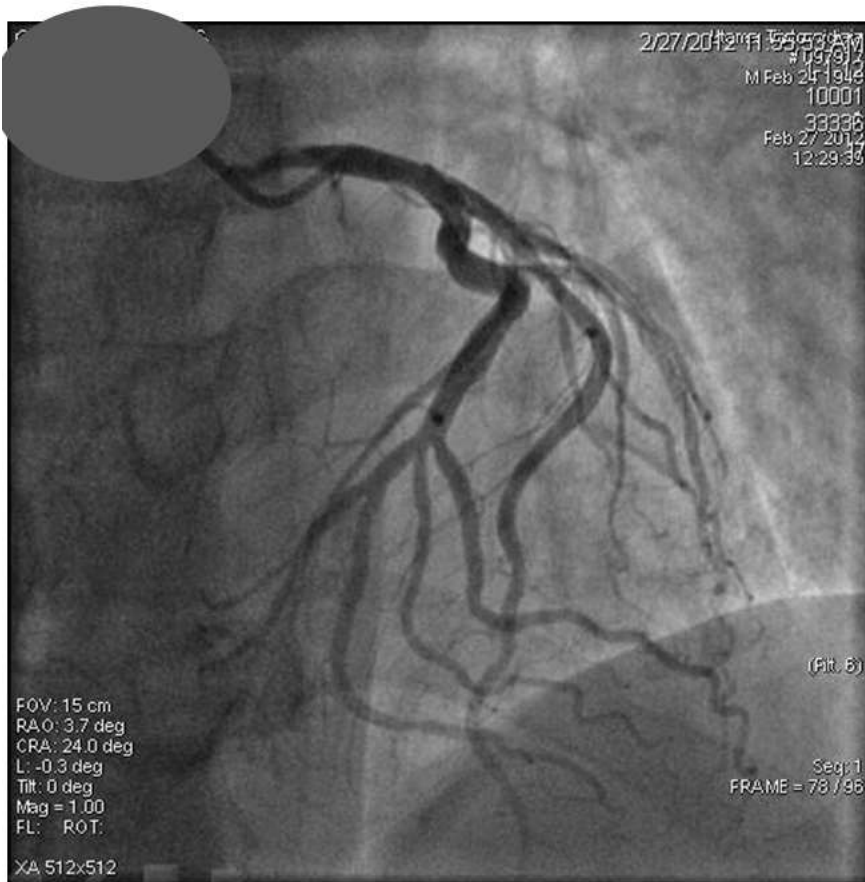
- **A 69 yo male came to our clinic with mild chest discomfort & left arm paraesthesia in July 2017**
- **CVRF: HTN & DM**
- **History of 4 x PCIs → total 5 implants (2009 to Mar 2017-- just 4 months prior) at RCA**
- **LCA Normal (2009-2017)**
- **Feb 2017 mild angina, but normal exercise treadmill test (1 week prior to the 4th PCI)**
- **July 2017: ECG no ST-T segment changes**
- **Chest X ray: Cor normal**
- **High sensitivity-Trop T: mild positive (30.0 ng/L)**
- **Echo: Moderate concentric LVH, Normal wall motion, LVEF 70%**

History of PCIs

2009	Mild angina	Prox RCA	Nobori 3.0-19
		Mid RCA overlappingly	Biomatrix 2.5-14
2012	Mild angina ISR prox RCA	Prox RCA	Biomatrix 3.0-18
2014	Mild angina ISR prox RCA again	Ostial-Prox RCA	BVS 3.5-18
2017	Mild angina ISR ostial RCA	Ostial-Prox RCA	DEB 3.5-18 + XA 4.0-23

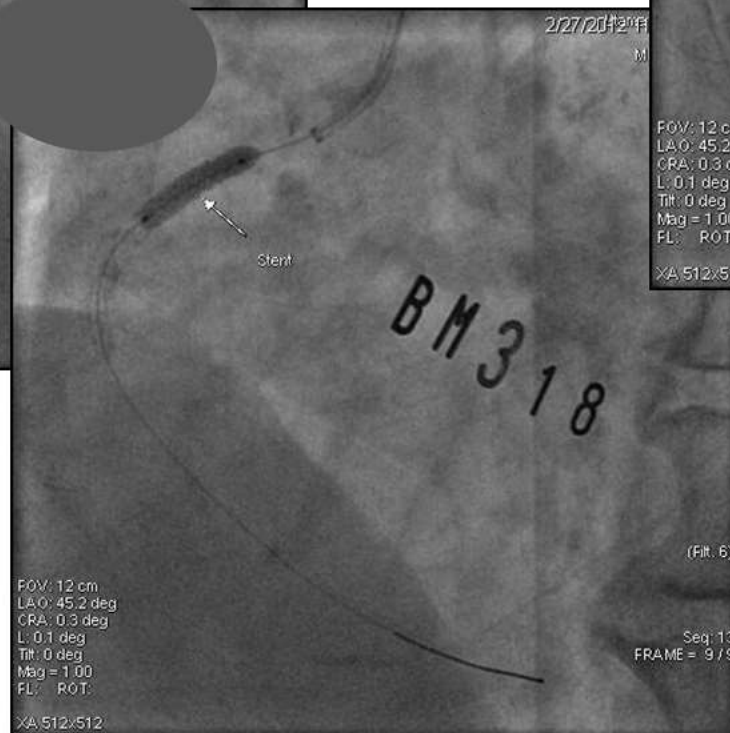
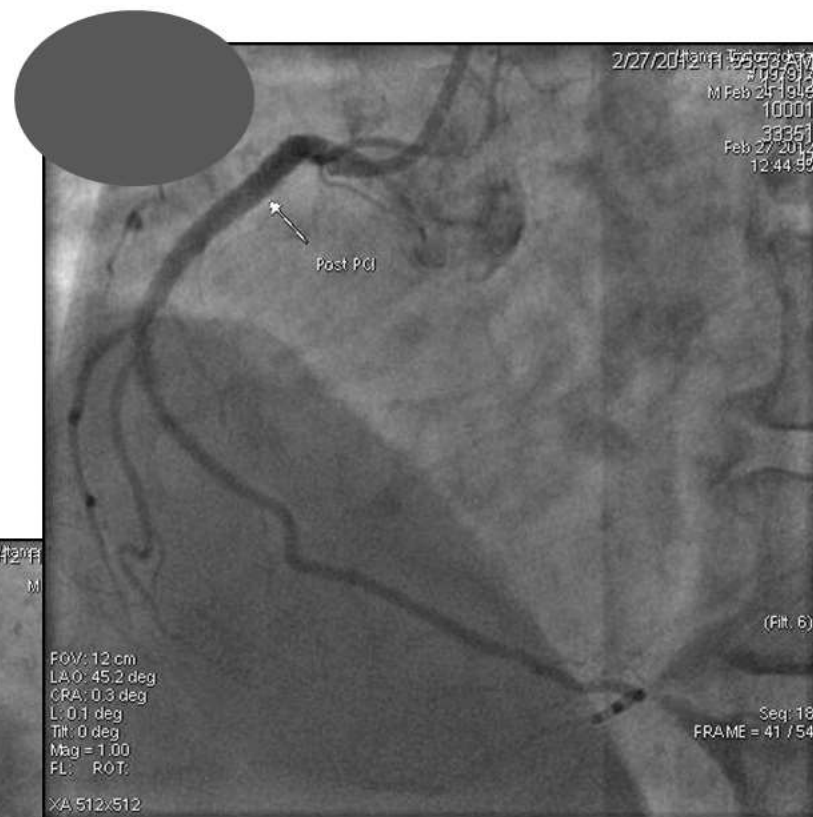
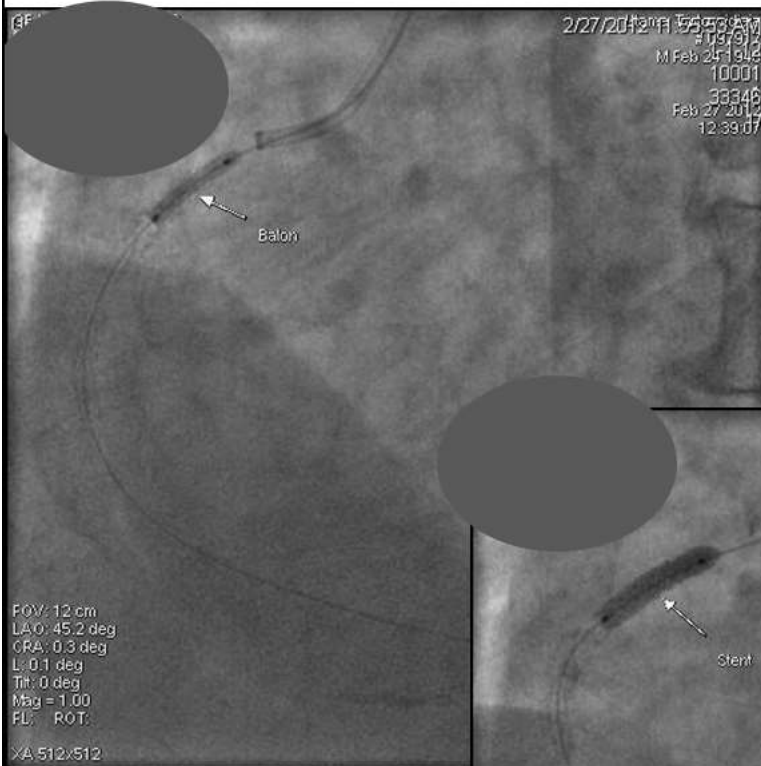
2012-DES ISR

Dominant LCA

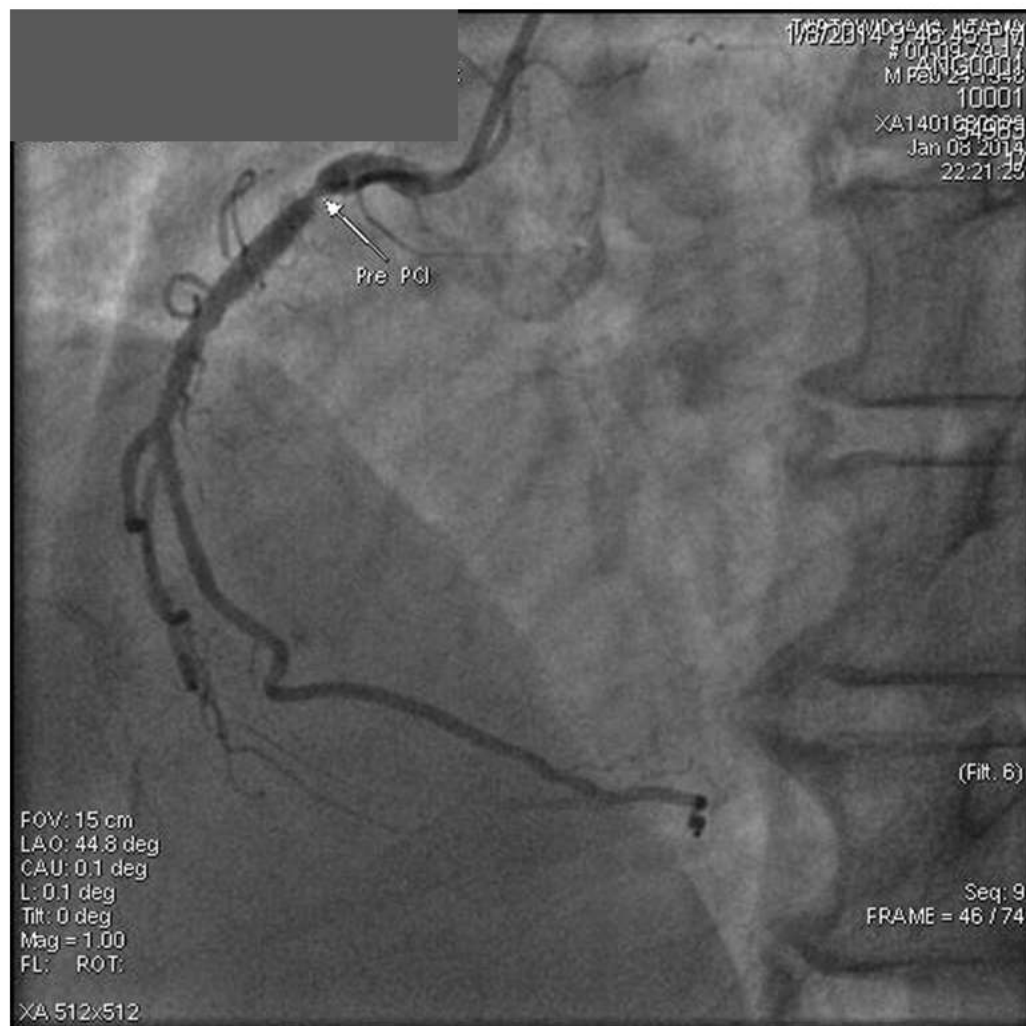


Non-dominant RCA

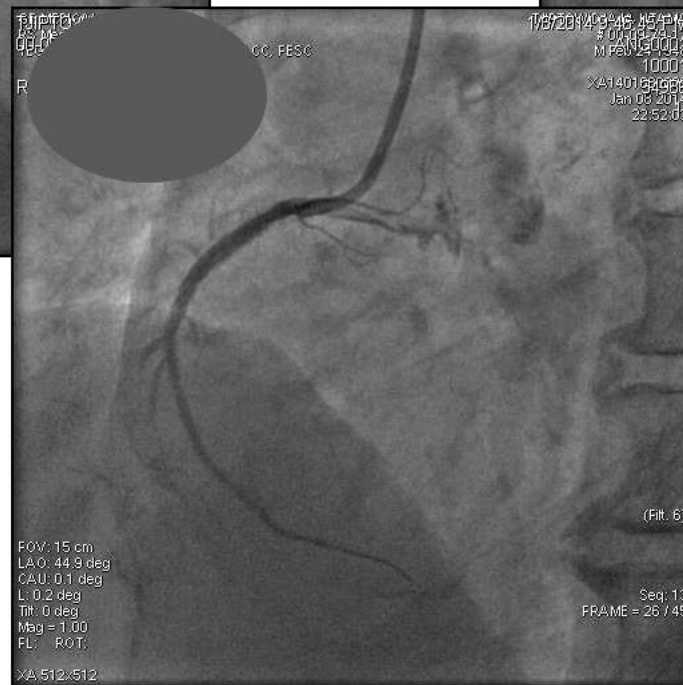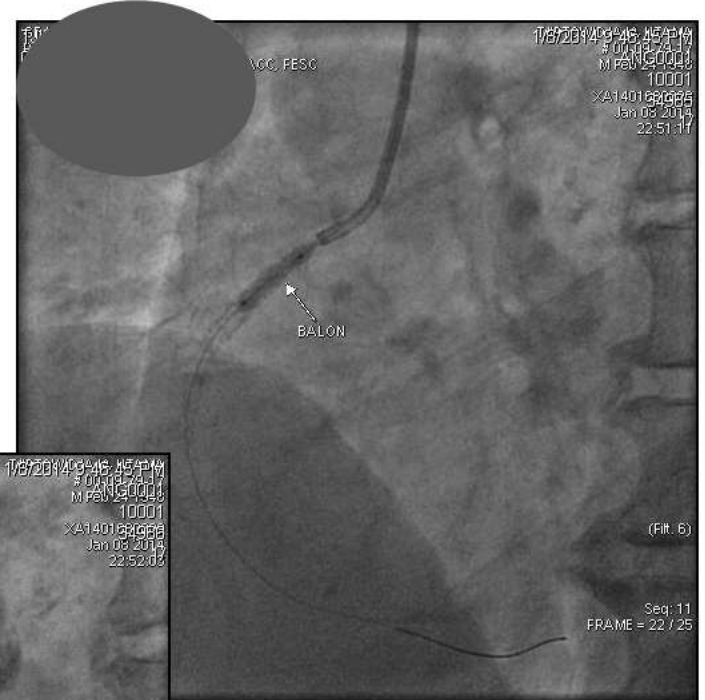
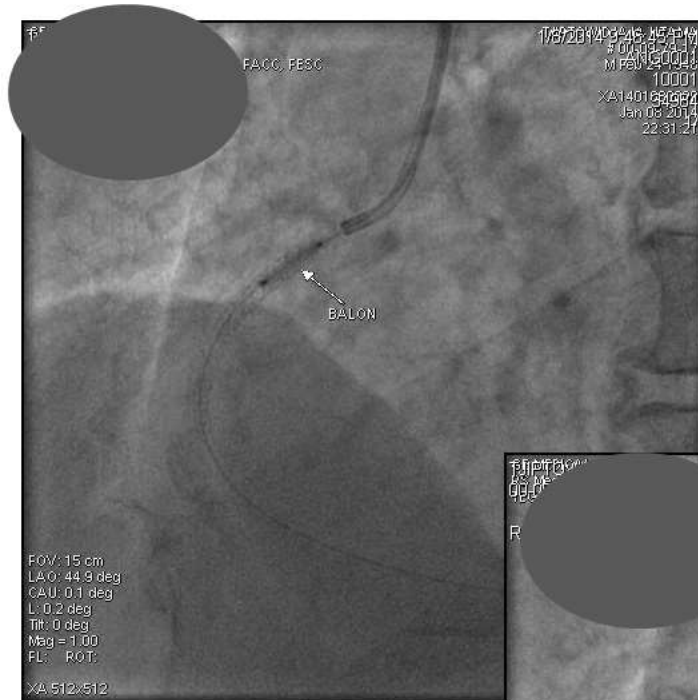
2012-DES



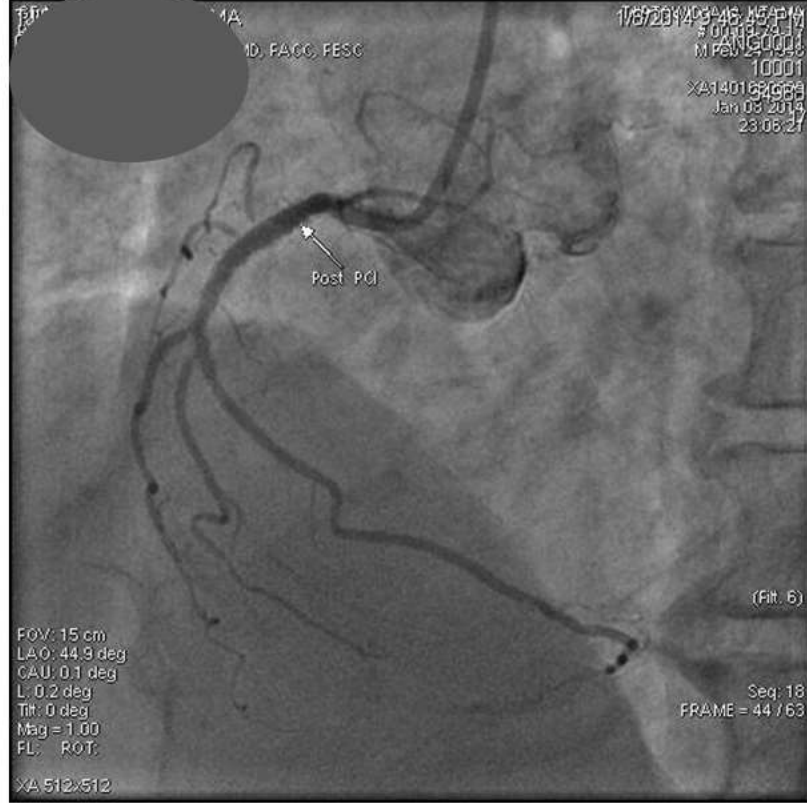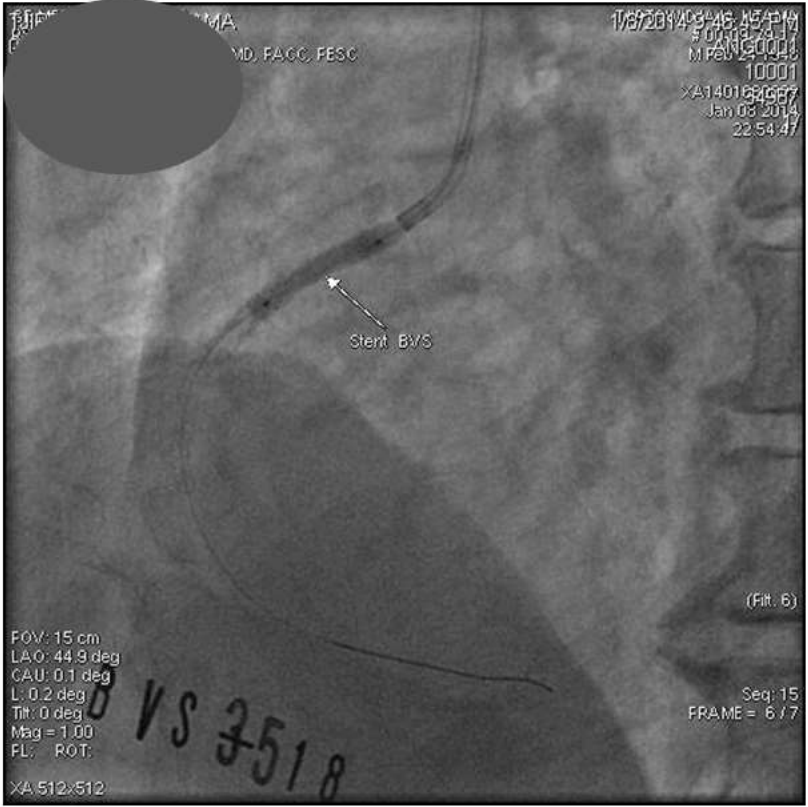2014-DES ISR



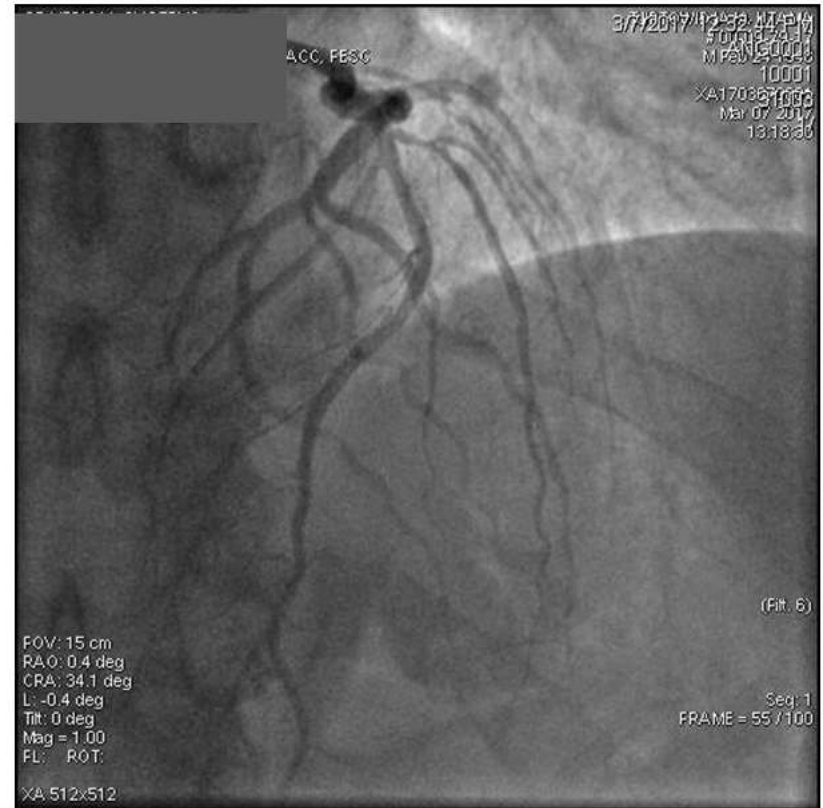
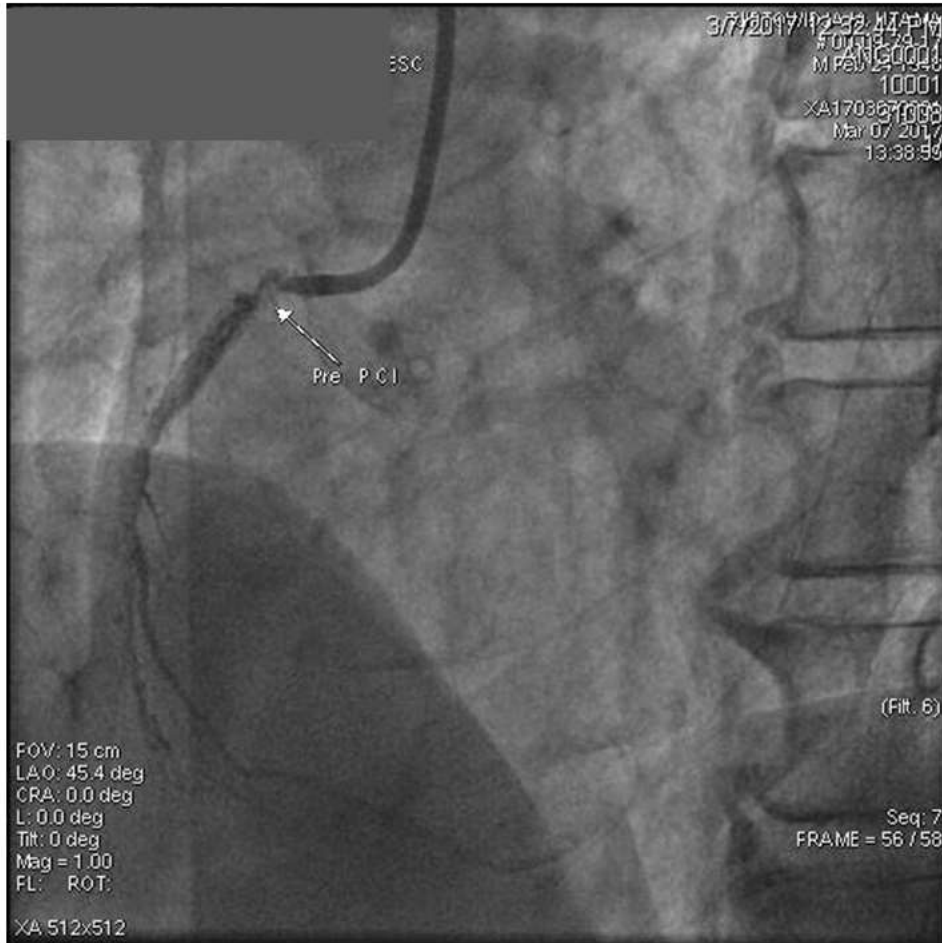
2014 Predilation



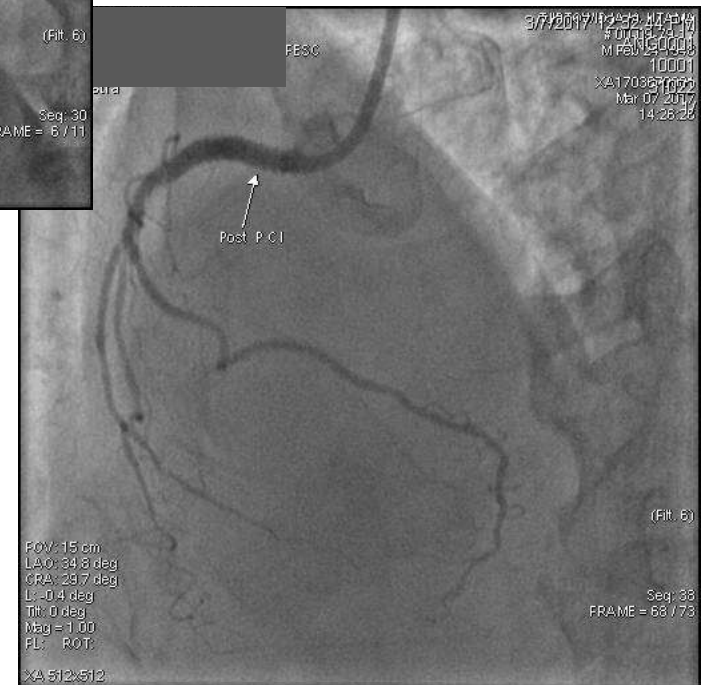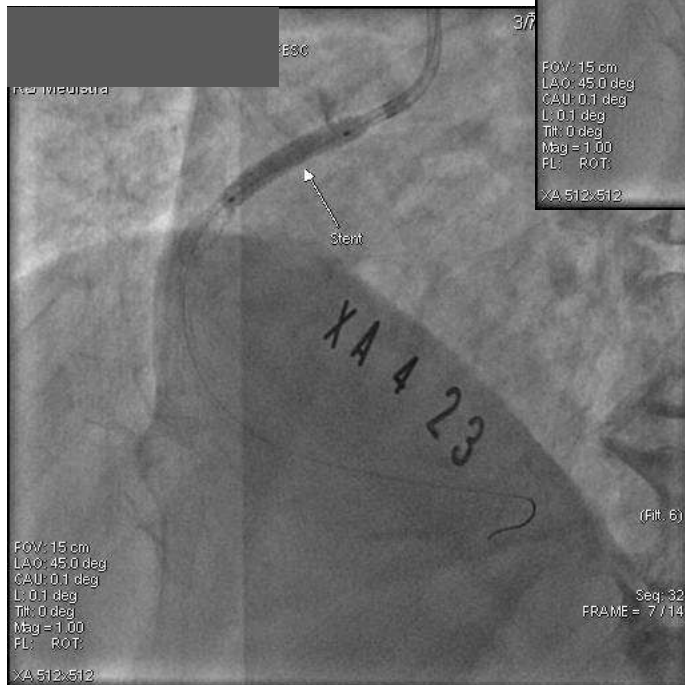
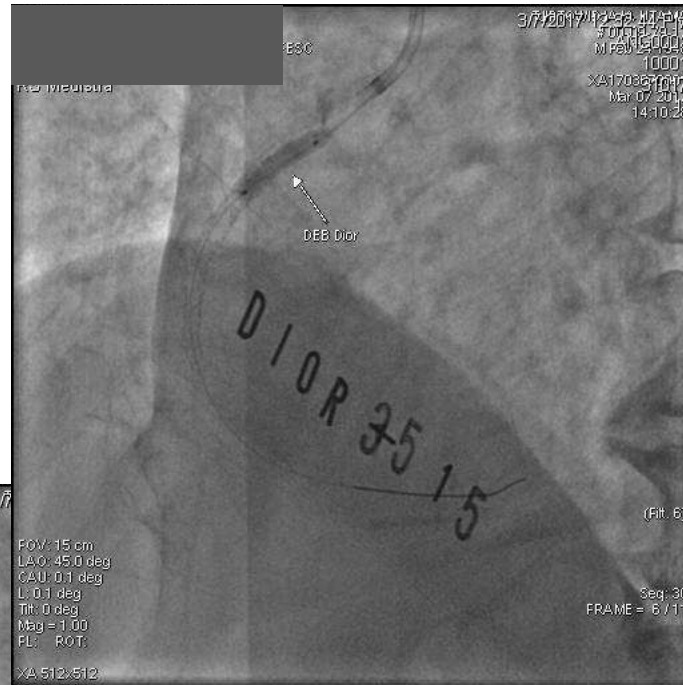
2014-BVS



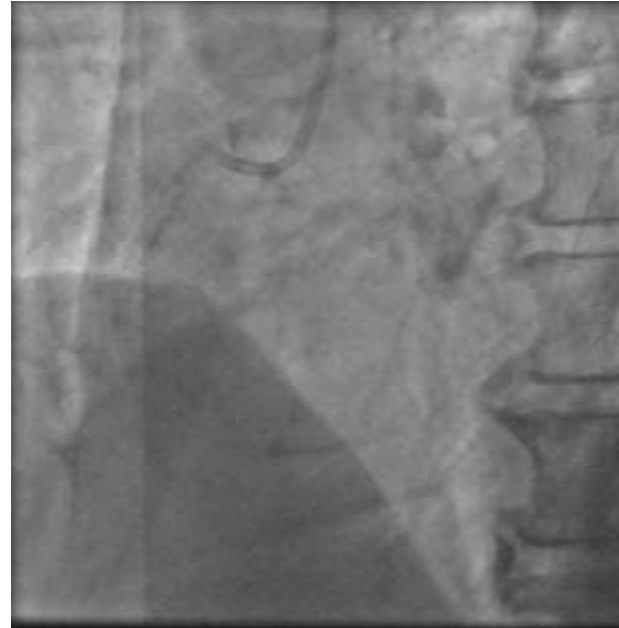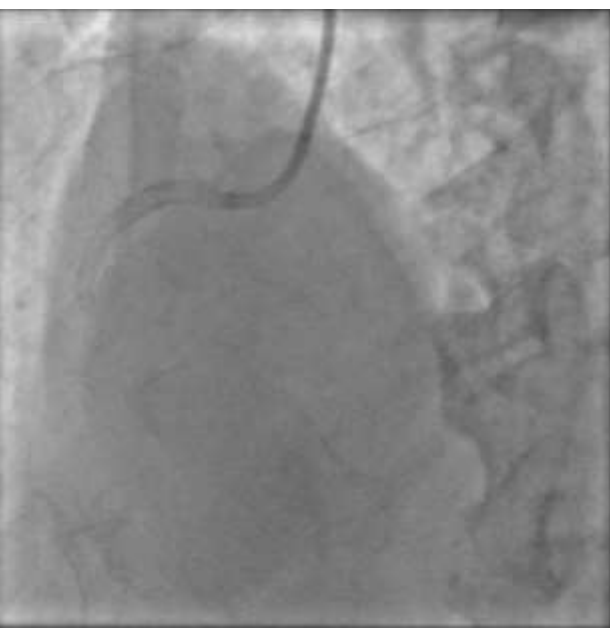
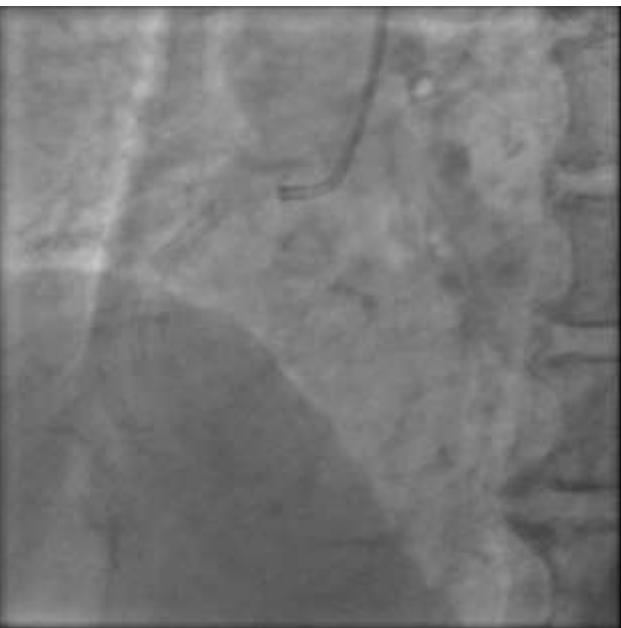
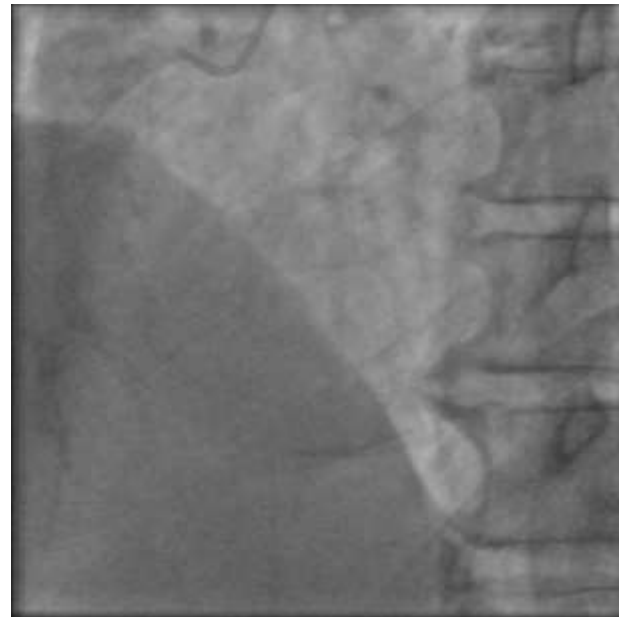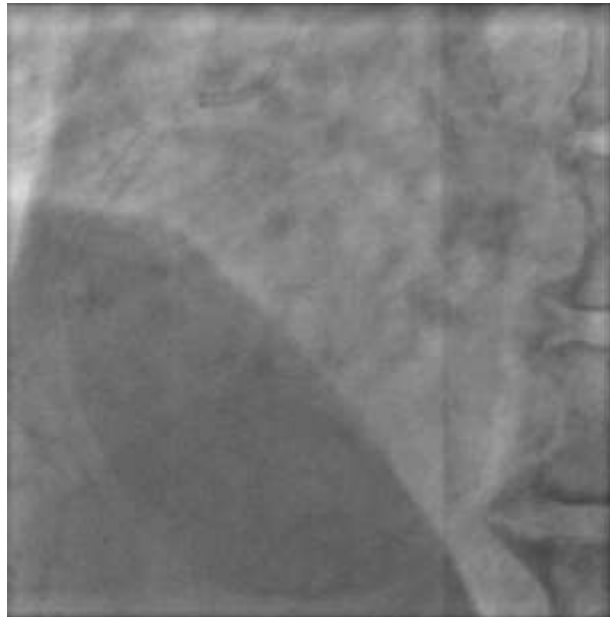
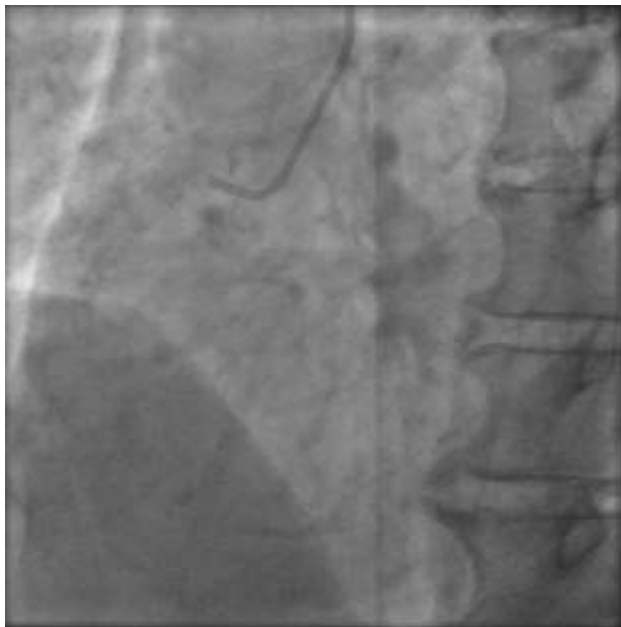2017 – BVS ISR



2017 DEB and DES

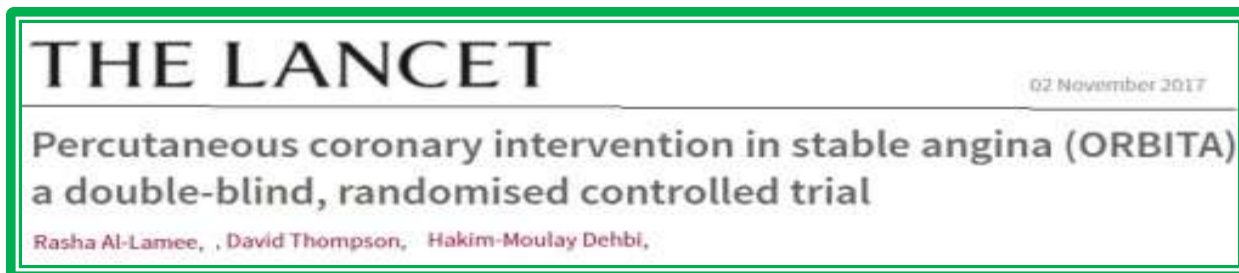

The Whole Cines



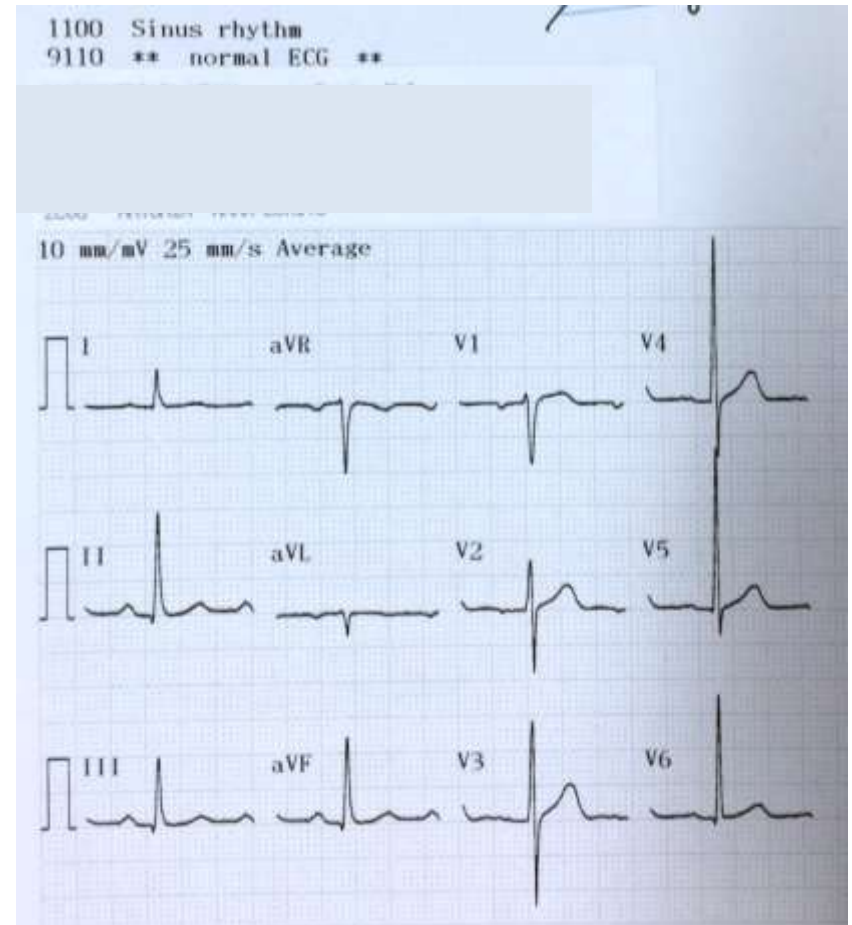
What should we do?

- **Angiography and stent RCA again?**
- **Angiography and RCA bypass surgery?**
- **OMT and let go the non dominant RCA ?**

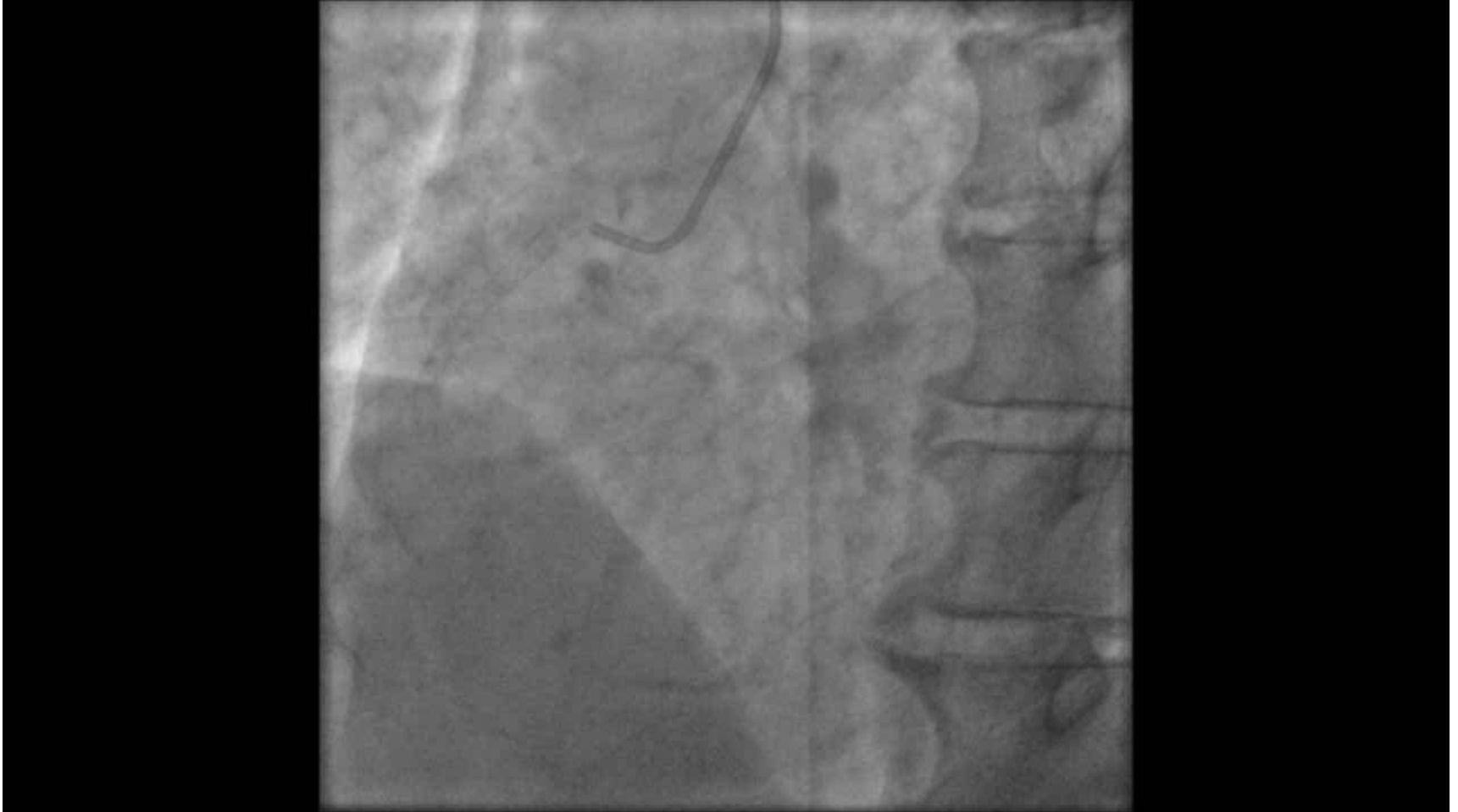

Follow-up

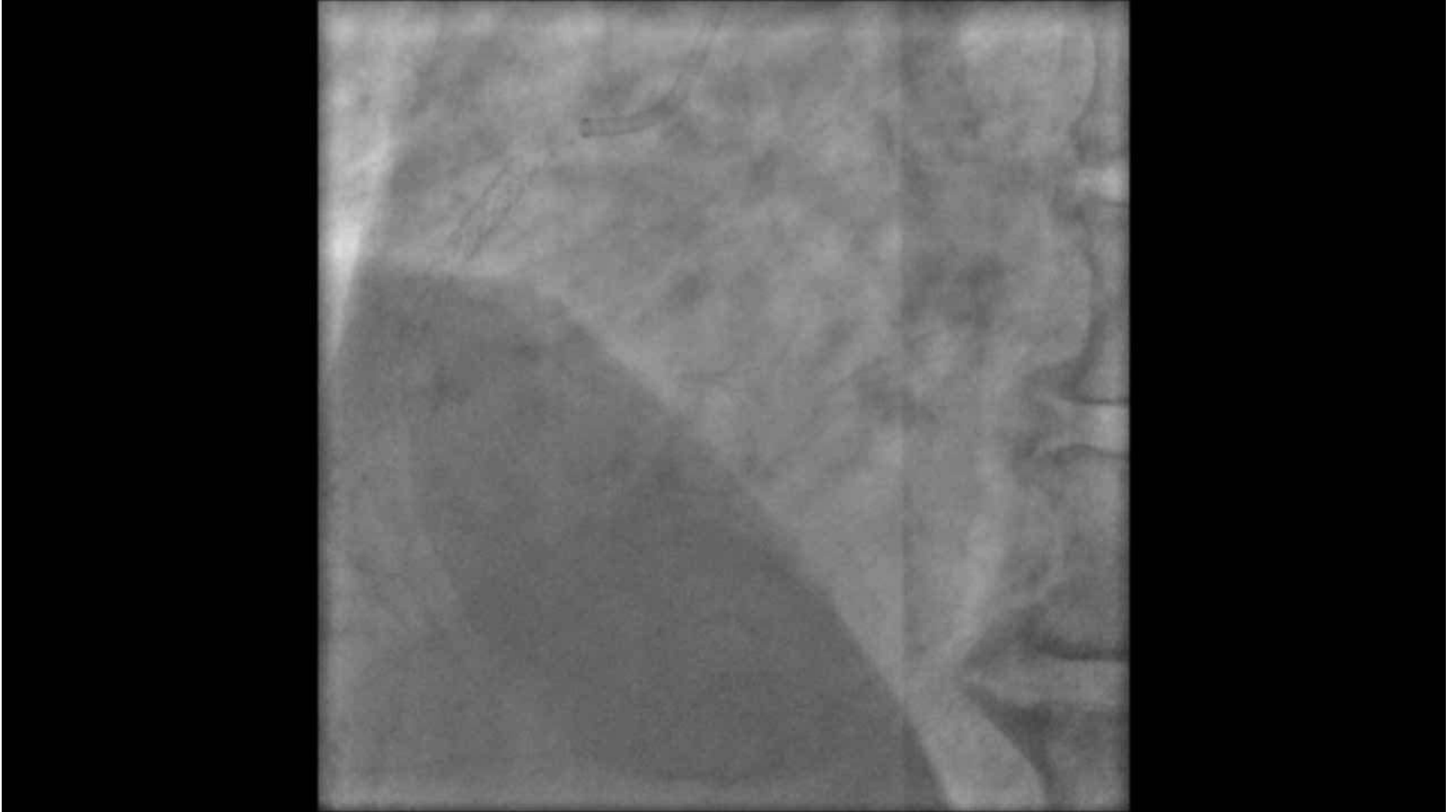
- Minimal angina
- ECG : normal
- Optimize antiangina medicine
- Three months F/up
 - No angina
 - Normal ECG



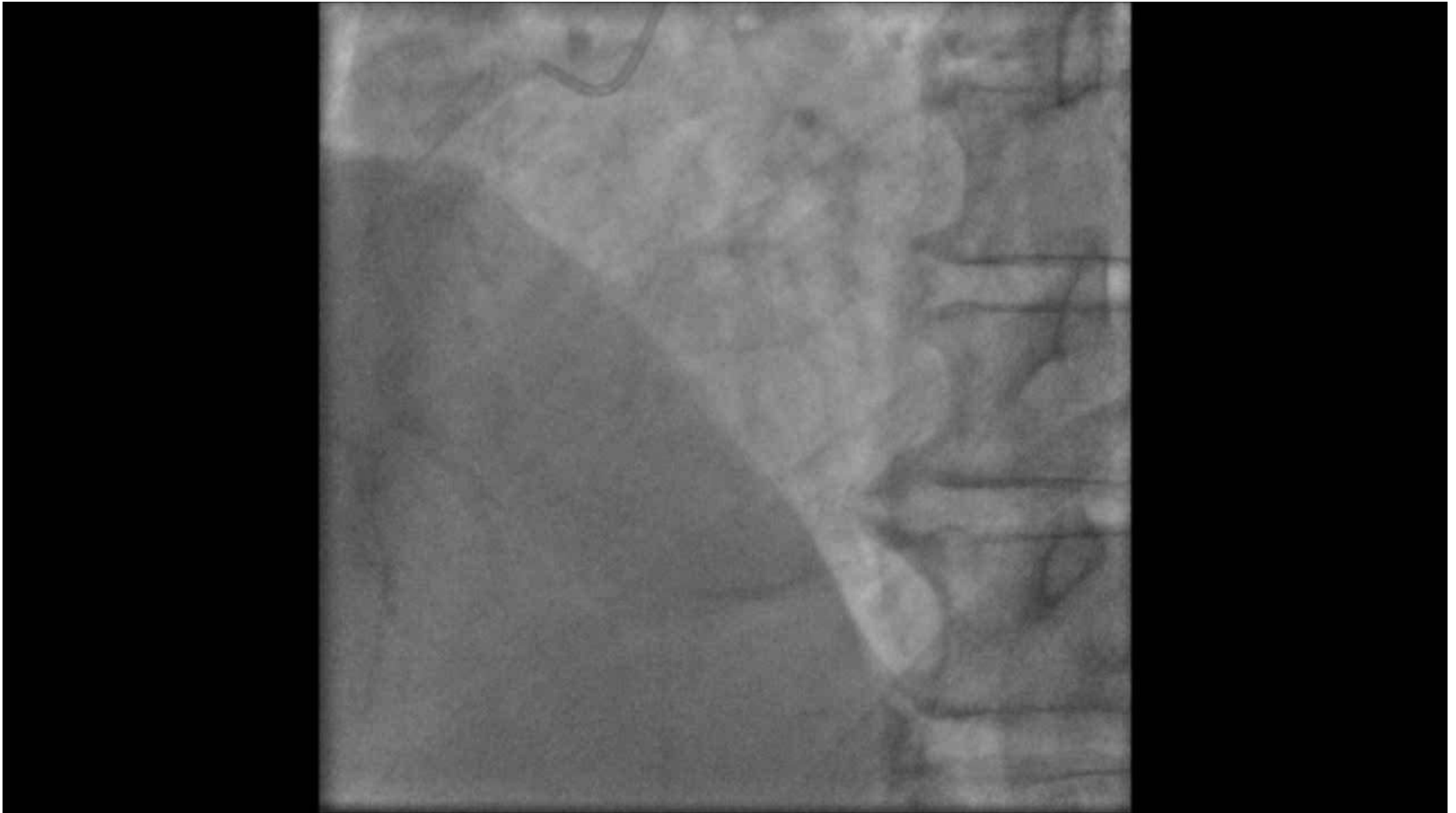
2012-DES ISR



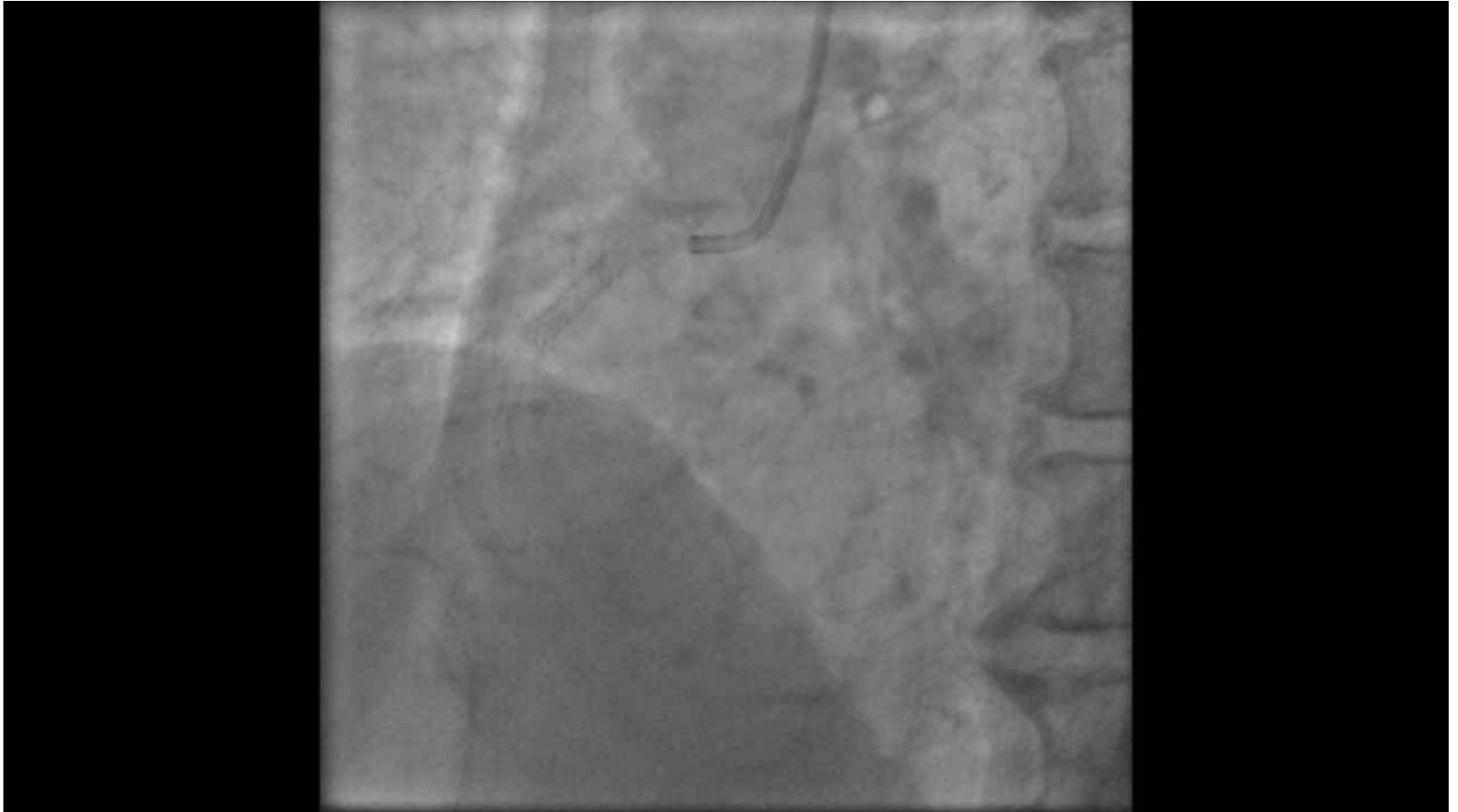
2012-PCI DES



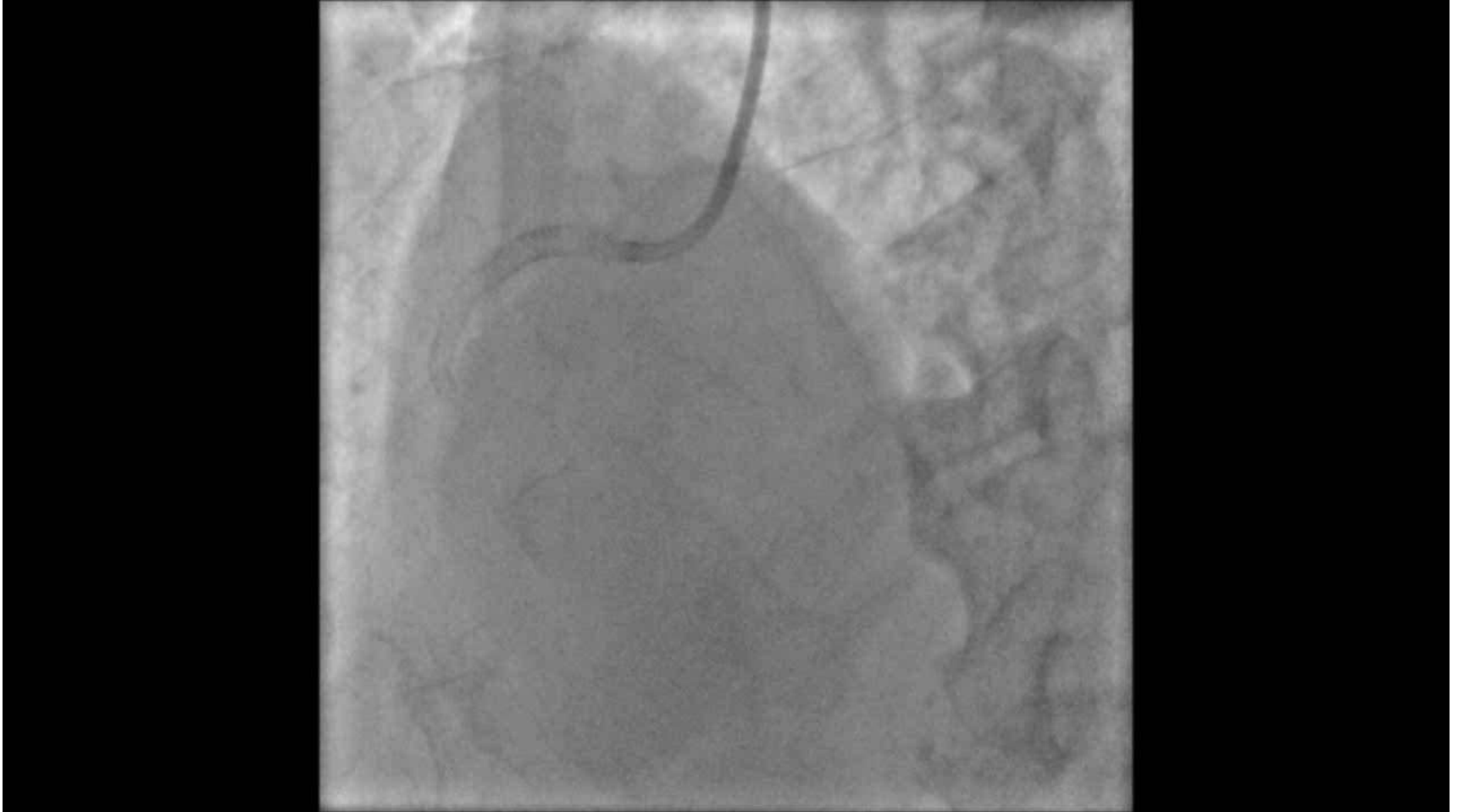
2014-ISR DES Again



2014-PCI BVS



2017- PCI DEB-DES



2017- BVS ISR

